ISOLATION AND PROPAGATION OF THERAPEUTICALLY-RELEVANT CELLS FROM SEVERELY DISEASED KIDNEYS TRANSLATES ACROSS RODENTS, LARGE MAMMALS AND HUMANS

inRegen
innovation in regenerative medicine

RUSSELL W KELLEY ERIC S WERDIN[1], ANDREW T BRUCE[1], SUMANA CHOUDHURY[1], SHAY M WALLACE[1], PATRICIA TATSUMI-FICHT[1], ELIAS A RIVERA[2], MANUEL J JAYO[2], TIMOTHY A BERTRAM[3], SHARON C PRESNELL[1]

Tengion Inc., Regenerative Medicine & Biology, Winston-Salem, NC; [2] Tengion Inc., Preclinical Development & Translational Medicine, Winston-Salem, NC;

ABSTRACT

Chronic Kidney Disease (CKD) often develops in patients with co-morbidities such as obesity, chronic hypertension, and metabolic disorders and is characterized by severely impaired renal filtration (uremia) and impaired erythropoiesis (anemia). The combination of a rising cost burden of dialysis on the healthcare system, a limited number of donor kidneys suitable for transplant, and the side effects associated with Erythropoiesis Stimulating Agents (ESAs) provide impetus for developing new treatment paradigms for CKD.

Aboushwareb et al (2008) showed that *ex vivo* cell cultures established from mouse whole kidney tissue contain highly-specialized cells that express erythropoietin (*Epo*) in addition to other kidney cell types[1]. Similar methods were used to establish cultures from rat kidney. *Epo*-producing cells, as well as tubular, ductal, vascular, interstitial, and glomerular cells were identified in the rat cultures by immunofluorescence and qRT-PCR. A pilot study was conducted, whereby intrarenal transplantation of the *ex vivo*-cultured rat cells in an established rodent model of progressive renal failure stabilized renal filtration and tubular functions, restored erythroid homeostasis, and prolonged survival versus untreated rats. These systemic observations were confirmed histologically, with clear demonstration of tubular and glomerular repair and regeneration, reduction of glomerular and tubulointerstitial fibrosis, stabilization of erythroid function, and reduction of bone catabolism. These results demonstrated that this heterogeneous culture contained therapeutically relevant cells.

Cell isolation was extended successfully to swine and human kidney tissue; with starting material isolated from CKD and non-CKD kidneys. All cell compartments identified in the rodent cultures were identified in swine and human cell cultures. Retention of functional proximal tubular cells in cultures propagated from both CKD and non-CKD kidney was demonstrated by receptor-mediated albumin uptake. *Epo*-expressing cells were also present in both CKD and non-CKD kidney-derived cultures and retained oxygen-responsive, HIF1-α-driven EPO expression during expansion.

Taken together, these results suggest that autologous sourcing of therapeutically-relevant cell populations is feasible in advanced CKD. Experiments are ongoing to identify the bioactive cellular component(s) responsible for the observed therapeutic benefits and establish potential methanism(s) of action.

RESULTS

Figure 1. Cell cultures established from rat kidneys contain all the major renal cell types: tubular, ductal vascular, interstitial, and glomerular.

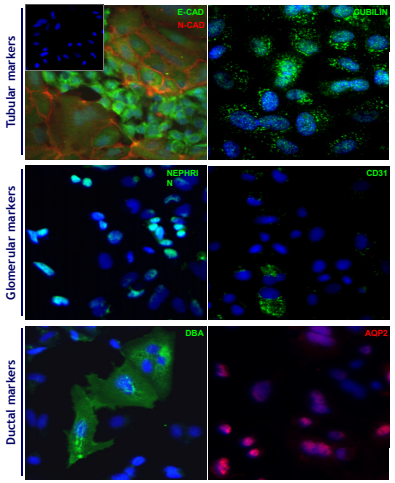

Cells were isolated and cultures established as described.[6,8] Rat protein expression was assessed using standard immunohistochemistry methods. Cells were isolated and passage 1 cultures established as described.[1,2] **Cell type identification was confirmed by detection of tubular markers: E-Cadherin (E-CAD), N-Cadherin (N-CAD) and Cubilin; glomerular markers: Nephrin; vascular: CD31 (PECAM); and ductal markers: Dolichos biflorus agglutinin (DBA) and Aquaporin 2 (AQP2).** Inset is IgG control staining.

Figure 2. Systemic assessment indicated that NK Cell treatment prevented CKD disease progression in an established rodent model

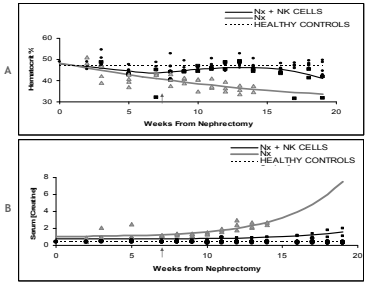

C

Assessment	Pre-Treatment Sham Nx	Pre-Treatment Nx	Post-Treatment Sham Nx	Post-Treatment Nx	Post-Treatment Nx + NK CELLS
HCT	45.4 ± 2.3	40.0 ± 2.5	45.6 ± 1.3	**38.9 ± 2.3**	47.0 ± 2.3*
RBC#	8.3 ± 0.3	7.6 ± 0.5	8.1 ± 0.2	**6.7 ± 0.6**	8.4 ± 0.1*
BUN	23.5 ± 2.1	**47.0 ± 4.0**	20.5 ± 1.0	**86.0 ± 12.2**	**43.5 ± 3.5***
sCREAT	0.5 ± 0.1	**0.8 ± 0.0**	0.4 ± 0.0	**2.3 ± 0.3**	**0.9 ± 0.0***
HB	nd	nd	13.8 ± 0.3	5.9 ± 0.4	11.2 ± 2.2*
sALB (g/dL)	nd	nd	3.8 ± 0.2	2.4 ± 0.1	2.8 ± 0.3
sTPRO (g/dL)	nd	nd	6.8 ± 0.4	5.0 ± 0.6	5.9 ± 0.1*
sPHOS	nd	nd	6.8 ± 0.7	10.0 ± 1.8	6.4 ± 0.5*
Survival (3-month)			100%	0%	100%

significantly lower than Sham Nx (Healthy)
significantly greater than Sham Nx (Healthy)
*significantly different than Nx post-treatment

Ex vivo-cultured rat cells were delivered intra-parenchymally into the remnant kidney of Lewis female rats at 7 weeks from 5/6 Nx (arrow on x-axis in graphs). The response over time of hematocrit (HCT) and serum creatinine (sCREAT) are shown in the panels A and B. Panel C summarizes the data for serum chemistry markers relevant to hematologic and kidney function: **At 12 weeks post-treatment (~19 weeks after nephrectomy) HCT, red blood cells number (RBC#), and hemoglobin (HB) in treated rats (Nx+NK CELLS) were statistically equivalent to healthy controls; BUN and sCREAT levels were significantly lower than untreated rats (Nx), but remained higher than healthy controls.**

Figure 3. Histopathological assessment of bone and kidney revealed that treatment with NK Cell prevented disease progression

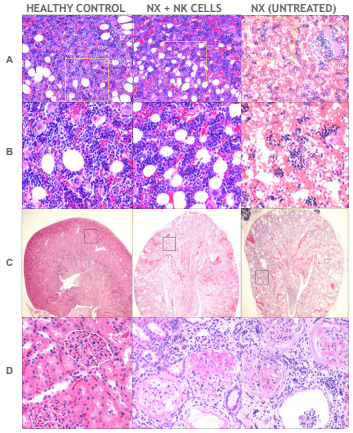

Representative H&E-stained histological sections of femoral bone marrow from each test group are shown in panel (A) (200x) with high magnification of boxed areas displayed in panel (B). Representative H&E-stained histological sections of kidney from each test group are shown at low magnification (10x) in panel (C) with high magnification (200x) of boxed areas displayed in panel (D). **Treatment with NK Cells prevented the loss of erythroid and myeloid cell precursors and the chronic renal changes characterized by severe glomerulopathy, tubular disease, interstitial inflammation and fibrosis, and tubular proteinuria that were observed in the non-treated Nx animals.**

Figure 4. Human and porcine kidneys with CKD-associated structural abnormalities remain sources for isolation and expansion of therapeutically active cell populations

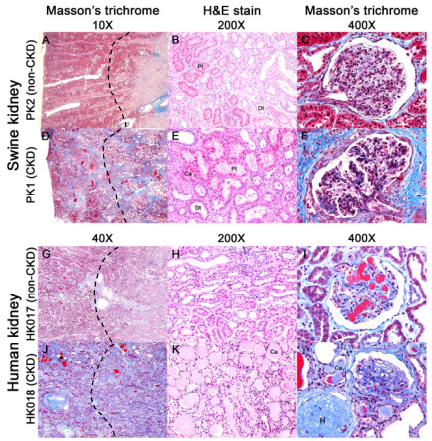

Panels A, B and C: representative histological sections of non-CKD swine kidney (PK2), showing **normal architecture** with well-demarcated cortical-medullary junction. Pt = proximal tubule, Dt = distal tubule.
Panels D, E and F: representative histological sections of CKD swine kidney (PK1), **showing progressive degeneration of kidney architecture** with diffuse periglomerular sclerosis, thickened Bowman's capsule, and increased number and prominence of mesangial cells in glomerular tufts. There is moderate tubulo-interstitial fibrosis and scattered chronic inflammatory cell infiltrates; proximal and distal tubular dilatation; proximal tubules filled with pink tubular casts (Ca).
Panels G, H and I: representative histological sections of non-CKD human kidney (HK017), showing mild degenerative changes with focal segmental glomerulonephritis where the glomerular capillaries contain fibrin deposition, suggestive of a coagulapathic disorder **(disseminated intravascular coagulation)**
Panels J, K and L: representative histological sections of CKD human kidney (HK018) showing progressive degenerative changes consisting of **marked distortion of renal architecture**, characterized by diffuse tubulo-interstitial fibrosis, pyelonephritis, tubular dilatation with proteinaceous casts (Ca) diffuse glomerural sclerosis and widespread replacement of glomerular tufts by avascular hyaline material (H).

Table 1. CKD-associated metabolic abnormalities do not hinder isolation and expansion of therapeutically active cell populations from human and porcine kidneys

Sample ID	Species	Cause of Death	BUN	sCREAT	HCT	HB	Key Histopathologic Features
PK001	Swine	Renal Failure	75	9.5	34.1	10.6	marked fibrosis, glomerular hypertrophy with focal sclerosis, tubular dilatation with protein casts
PK002	Swine	Sacrifice	na	na	na	na	normal kidney histology
HK016	Human	Head Trauma	13	0.4	26.6	9.6	normal neonatal kidney histology
HK017	Human	CVA	12	2.9	na	na	normal tubular histology; no fibrosis; fibrin thrombi throughout glomerular capillaries
HK018	Human	CV / Renal Failure	40	8.6	24.6	8.1	marked fibrosis; glomerular sclerosis; tubular dilatation with protein casts
5/6 Nx Rat Model	Rat (Lewis/F)	Renal Failure	105.5*	2.58*	35.6*	5.9*	fibrosis; glomerular atrophy and sclerosis; tubular degeneration and dilatation
Healthy Rats (Age-Matched)	Rat (Lewis/F)	Sacrifice	19.4*	0.35	46.4	13.7	normal adult kidney histology

Donor PK001 was an adult male breeder pig with a >8 month history of idiopathic renal failure. HK018 was a 48 year old female donor with a history of hypertension, type II Diabetes Mellitus, and chronic renal failure with 6+ years of dialysis. Renal function was assessed by BUN and sCREAT values at the time of death when available. Erythropoietic function was assessed by HCT and HB values when available. Values outside of normal range are presented in **BOLD**. All donor tissues were sampled and subjected to routine histopathologic analyses to identify CKD-associated attributes.

Kidney function is clearly compromised in CKD specimens (PK001 and HK018), highlighted by the significant increase in BUN and sCREAT. Furthermore, mild deficits in hematocrit (HCT) and/or hemoglobin (HB) are noted in the human CKD subjects, indicative of the anemia that typically accompanies the advanced stages of renal failure. Values for an established rodent model of chronic renal failure (the 2-step 5/6 surgical nephrectomy model)[3] illustrate the structural and metabolic similarities in disease states between the spontaneous CKD in human and porcine samples and the rat model.

All tissue specimens were collected in compliance with institutional guidelines governing the handling and use of tissues from human donors and laboratory animals. Human specimens were provided by the National Disease Research Institute (NDRI). Swine specimens were collected at the University of North Carolina at Chapel Hill. Rodent specimens were procured through Charles Rivers Laboratories.

Figure 5. *Ex-vivo* tubular cell function confirmed in cultured rat, swine, and human cells

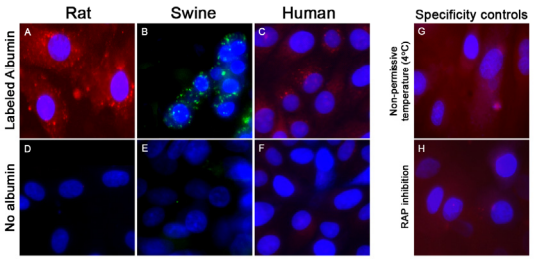

An albumin uptake assay was used to confirm tubular activity in cultured kidney cells derived from rat (A, D), swine (B, E), and human (C, F) kidney tissues. Rhodamine (A, C) or FITC (B) conjugated albumin was used to measure Megalin:Cubilin mediated protein uptake. Punctate fluorescence indicates albumin uptake in rat (A), swine (B), and human (C) tubular cells. Negative control (no albumin) is shown for each species (D-F). Specificity of the albumin uptake was confirmed by conducting the assay at a non-permissive temperature (4°C) (G) or by the addition of RAP (H), a competitive inhibitor of receptor-mediated albumin uptake.

Figure 6. Growth kinetics of cells isolated and expanded from CKD tissue mimic those isolated from non-CKD tissue

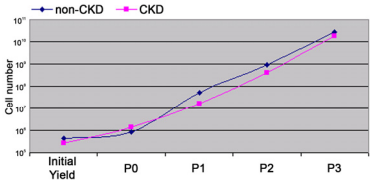

Growth kinetics of human non-CKD and CKD kidney cell culture. Cultures established and serially passaged from human kidney tissue. **The growth kinetics of CKD and non-CKD derived cell cultures strongly overlap.**

Figure 7. Oxygen-Regulated expression of EPO mRNA levels in cultured rat, swine, and human cells.

SAMPLE	EPO EXPRESSION 21% O2	2% O2	Fold Increase
PK001	0.363	2.427	**6.7**
PK002	0.21	2.32	**11.0**
HK016	0.162	0.702	**4.3**
HK017	0.249	0.769	**3.1**
HK018	0.271	0.464	**1.7**
RK	0.685	1.612	**2.4**

Cultures established and serially-passaged from swine and human kidney tissue were maintained at 21% O_2 for 48 hours then placed for 24 hours at either 2% or 21% O_2. RNA samples were collected and compared via qRTPCR. **Lowering oxygen levels consistently induced Epo expression across species.**

CONCLUSIONS

- ***Ex vivo* cell cultures established from rodents are therapeutically active:**
  - ***Functional renal tubular cells***
    - Stabilized renal filtration and tubular functions
  - ***Bioresponsive Epo-producing cells***
    - Restored erythroid homeostasis
  - ***Prolonged survival***
- **Despite clear differences in tissue architecture between non-CKD and CKD specimens, cultures established are remarkably similar**
  - ***Morphology & growth kinetics***
  - ***Marker expression patterns***
  - ***Functional attributes***
- **These results suggest that autologous sourcing of therapeutically active cell populations is feasible in advanced CKD.**

References cited:

1. Aboushwareb T, Egydio F, et al. (2008) World J Urol 26, 295-300.
2. Joraku A, Stern KA, et al. (2009) Methods 47, 129-133.
3. Lameire N, Van Biesen W, et al. (1998) Kidney Int 54, 2194-2206.